

# Wound bed preparation for dermal template using a hydrogel and a superabsorbent dressing.

## Wound bed preparation of a sacral pressure injury for dermal template using autolytic debridement

**Joey Vizconde Lubrica**

Clinical Nurse Specialist -Wound Care District Nursing, Northern Region, Te Whatu Ora - Health New Zealand

### SITUATION

A 65-year-old male bed bound patient with a BMI of 16 kg/m<sup>2</sup>, a schizoid personality disorder, former strong alcoholism and an MCA stroke in 2019 with low rehabilitation potential, was presented with a sacral pressure injury to the District Nursing Service.

### ACTION(S) TAKEN/ TREATMENT PROVIDED

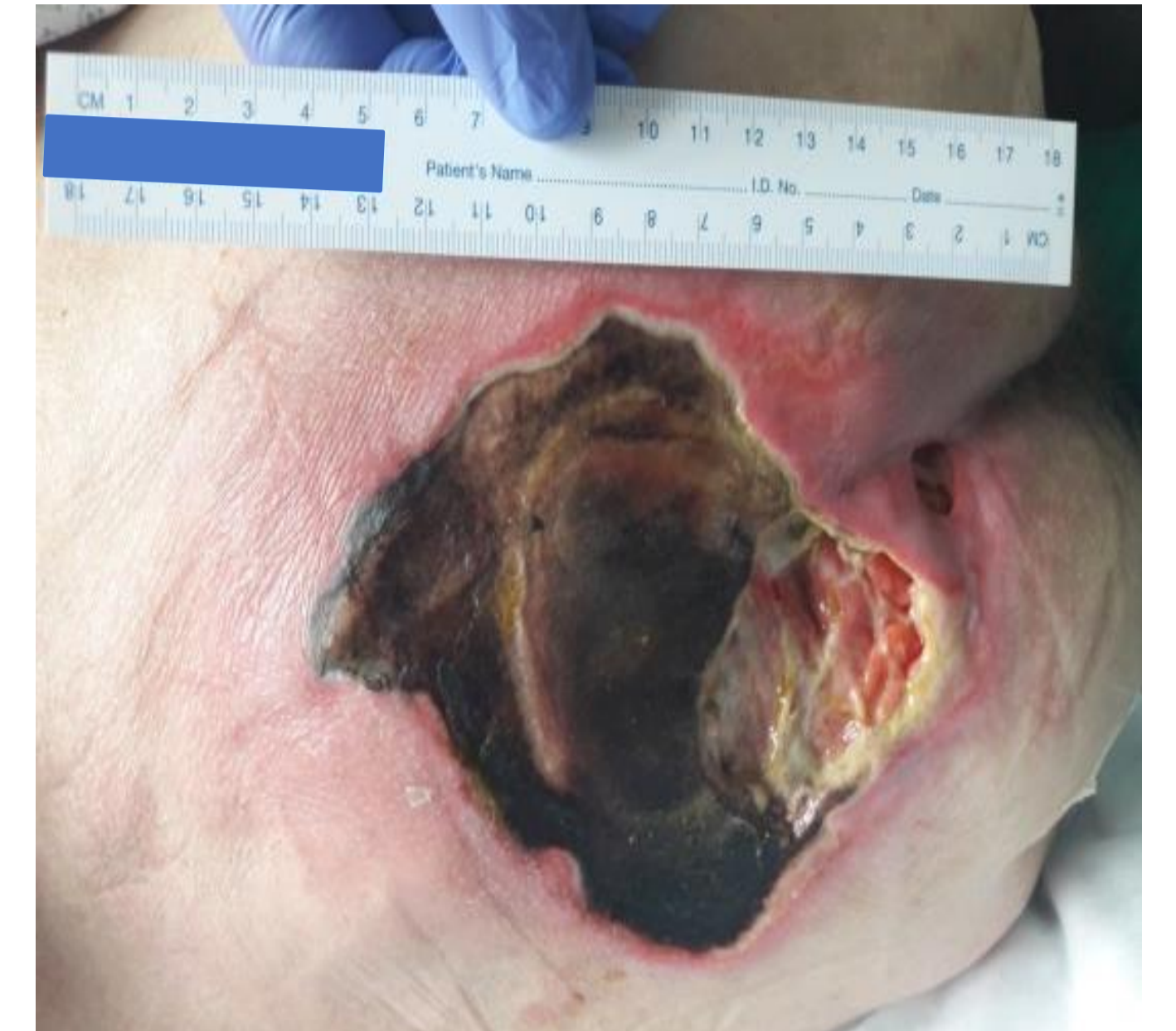The pressure injury (Picture 1) was subjected to sharp debridement to remove the hard necrotic tissue. For further autolytic debridement, the wound was treated with a hydrogel wound dressing\*. For exudate management, a superabsorbent wound dressing\*\* was used as a secondary association. In the first week, the wound was additionally debrided mechanically. However, since this resulted in more arterial bleeding, treatment completely switched to autolytic debridement. Dressing changes were completed daily by Rest Home staff with weekly input from the District Nurse.

### OUTCOME(S)

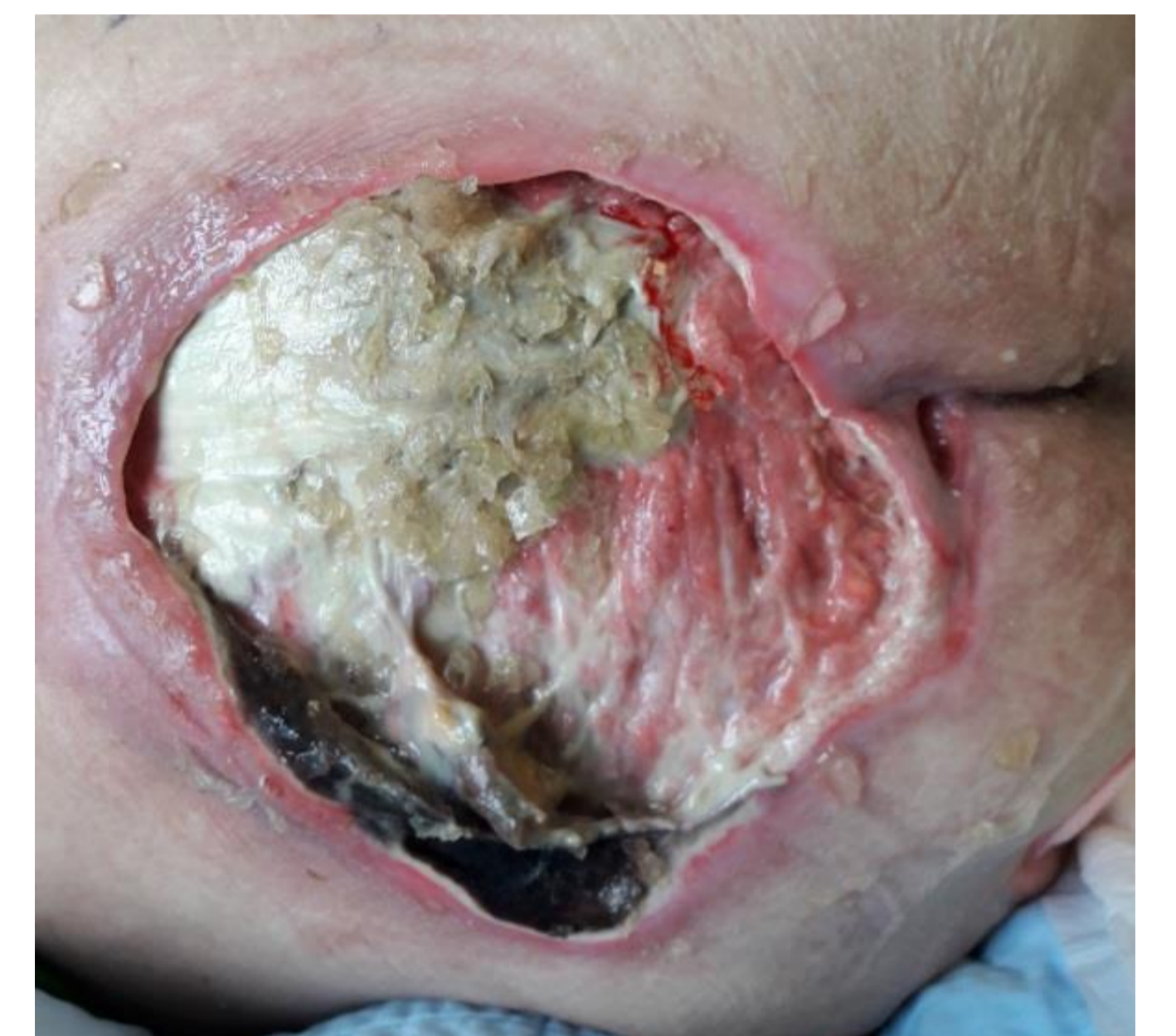After 5 days (Picture 2) of autolytic debridement, dark eschar started to soften. Further maceration of the peri wound skin was prevented by the superabsorbent dressing via absorbing high quantities of exudate. After 15 days (Picture 3), the necrotic areas were starting to lift up. Granulation on some areas of the wound bed developed. After 28 days, some edges of the wound bed had partially healed. After 43 days (Picture 4) the wound had healed to such an extent that autolytic debridement was no longer indicated, and application of a dermal template commenced.

### LESSON(S) LEARNED

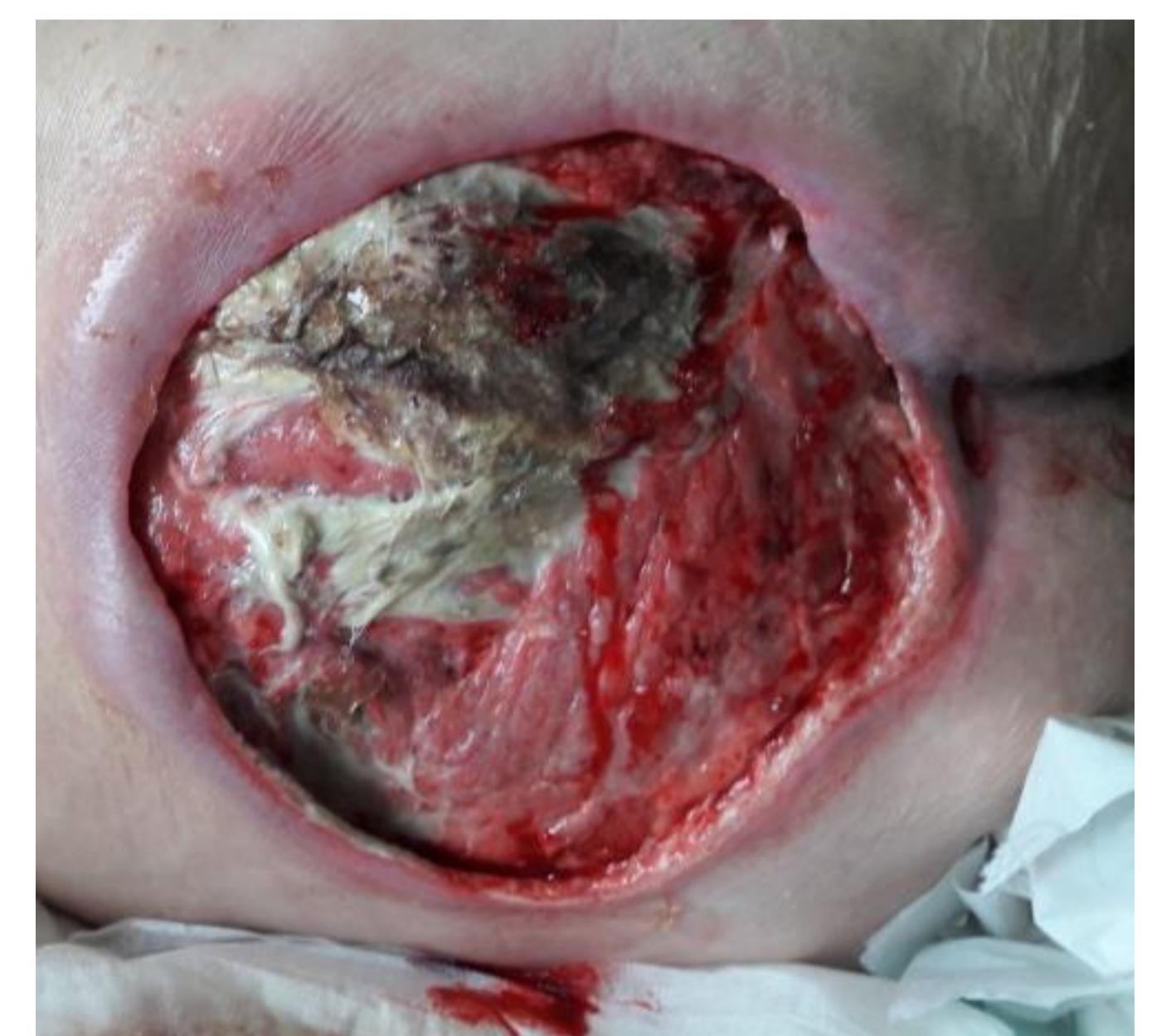Considering the patient's comorbidities, the hydrogel wound dressing in combination with the superabsorbent dressing were able to debride and prepare the wound bed for the next step of application with a dermal template.



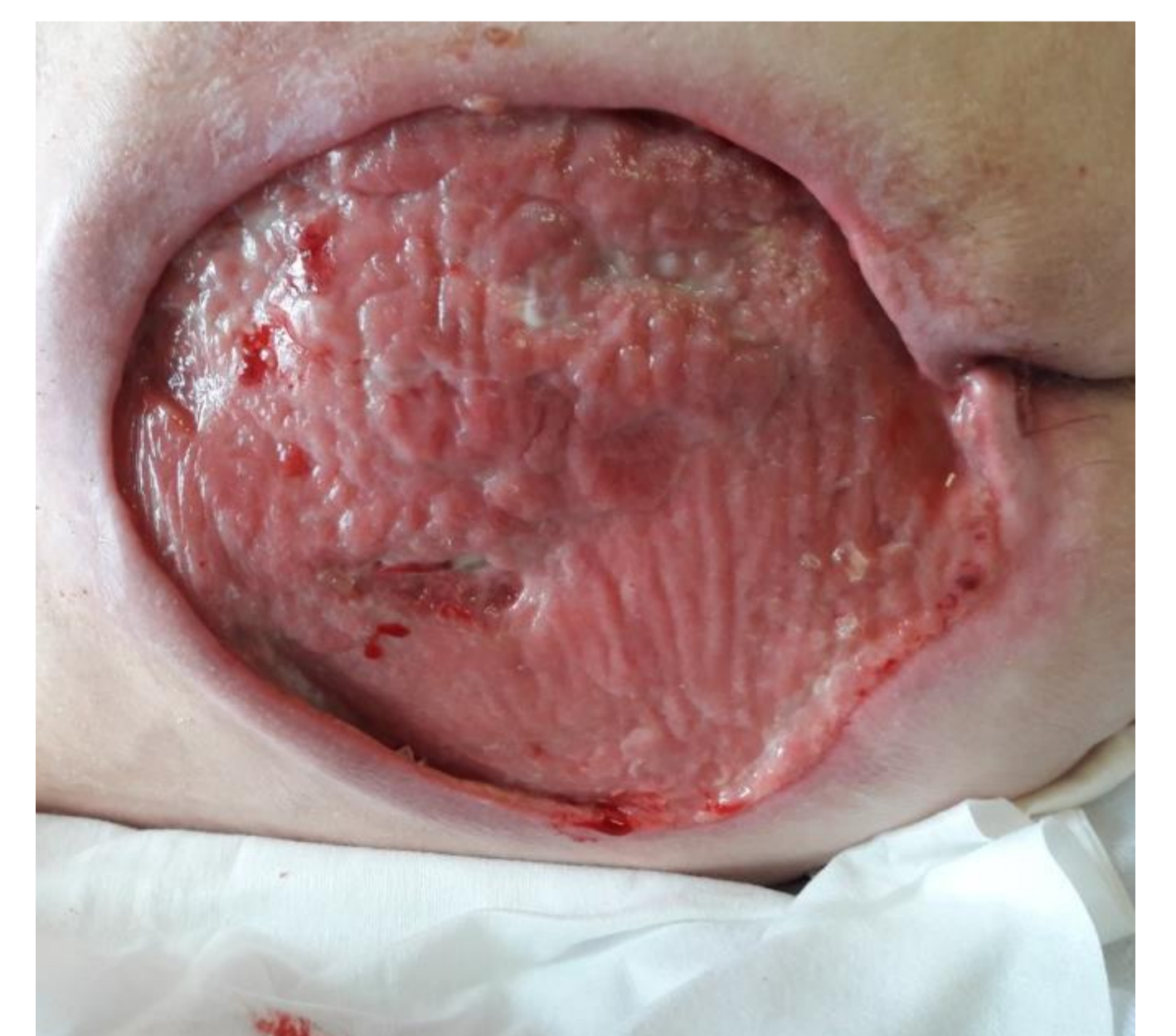**Picture 1:** Initial Situation



**Picture 2:** Day 5



**Picture 3:** Day 15



**Picture 4:** Day 43


\* Suprasorb G

\*\* Vliwasorb Pro

Lohmann & Rauscher Pty Ltd



For more information on the products used, visit the L&R publication database.



**WOUNDS AUSTRALIA  
2022 CONFERENCE**  
14-17 September 2022 | ICC, Sydney  
Time to Heal | Time to Unite | Time to Innovate